

Exhibit 8

Round Opacities (pqr)

174

Stuart M. Bracks

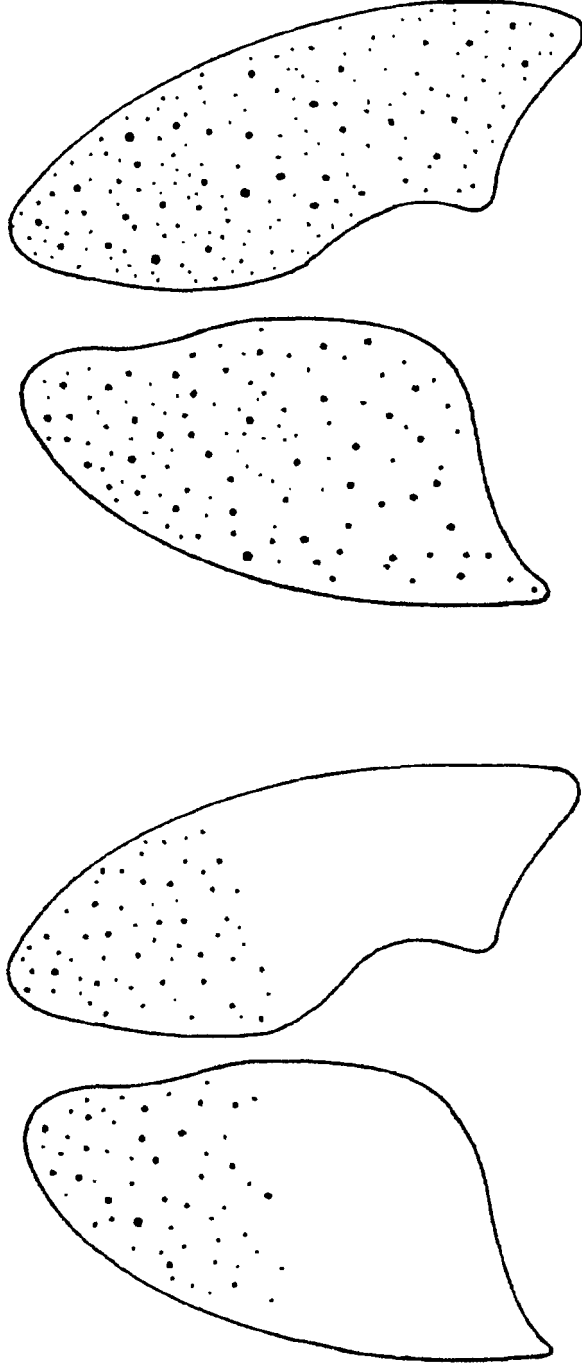


Figure 1. Chest x-ray pattern showing rounded rounded regular opacities. The pattern of early disease located mainly in the upper and mid lung fields is shown on the left, while the pattern of more advanced disease is shown on the right.