

# Exhibit 9

# Irregular Opacities (stu)

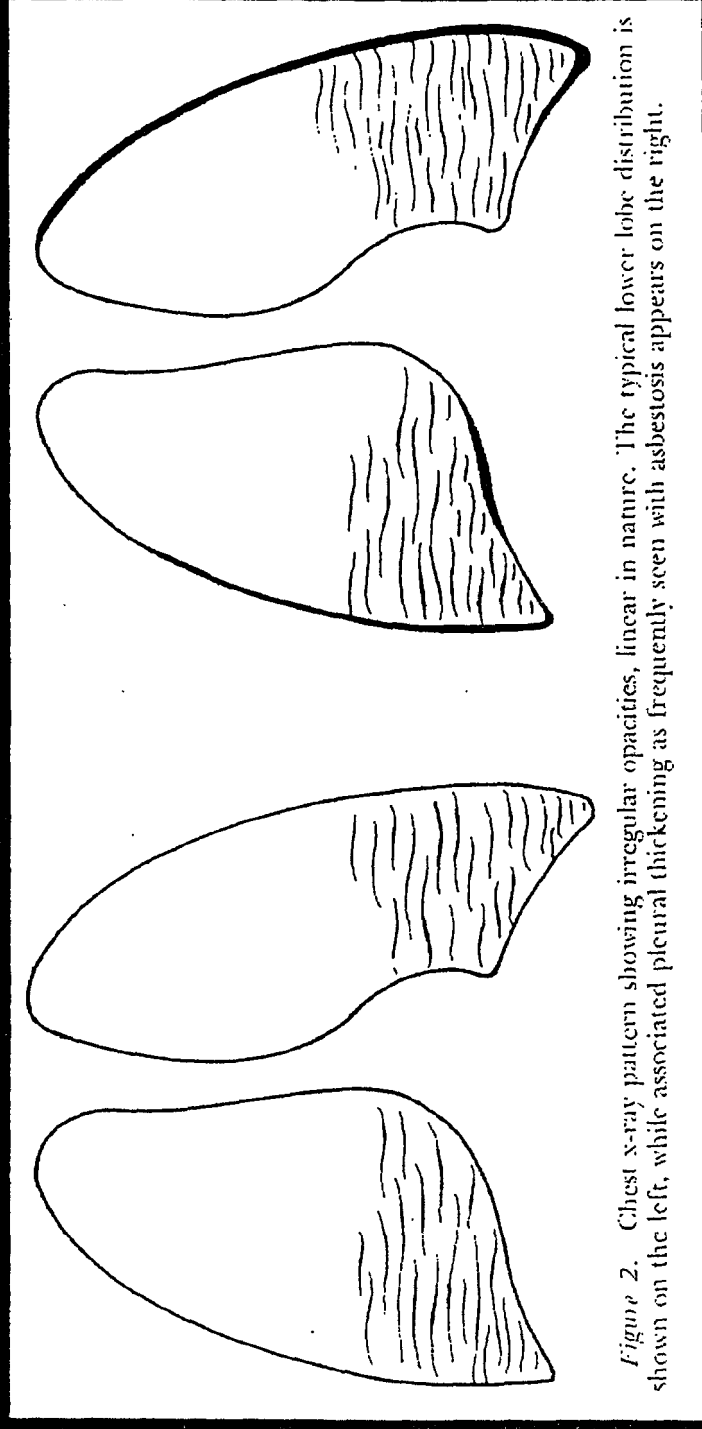


Figure 2. Chest x-ray pattern showing irregular opacities, linear in nature. The typical lower lobe distribution is shown on the left, while associated pleural thickening as frequently seen with asbestosis appears on the right.